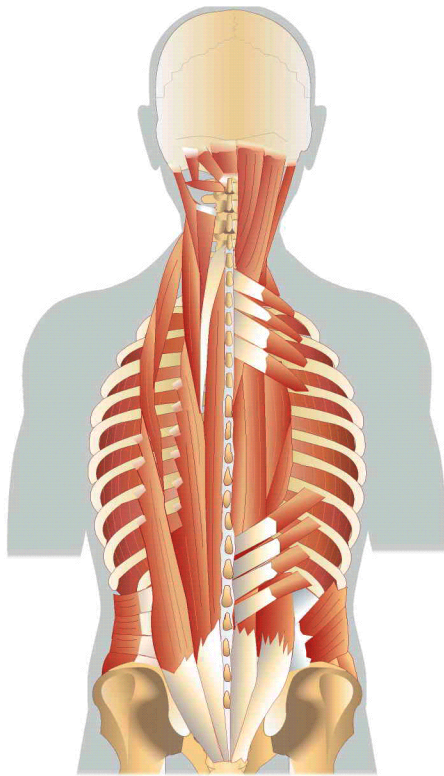
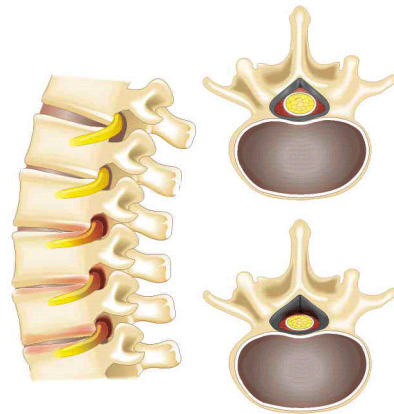
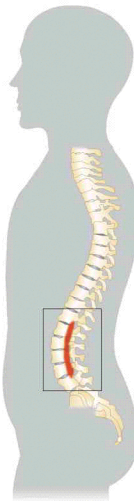



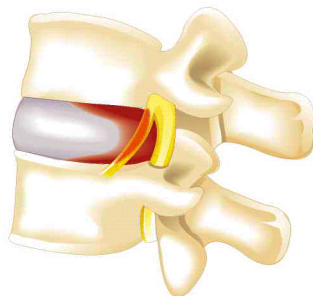
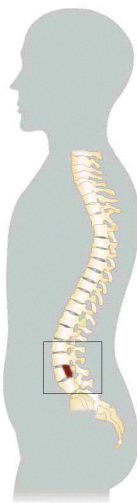**Low Back Anatomy**



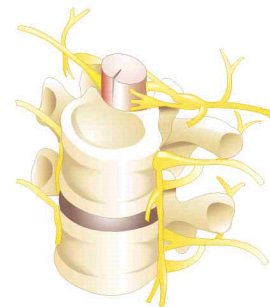
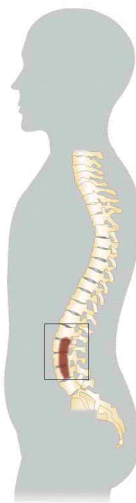Lower back



Spinal stenosis



Herniated disc



Degenerative disc disease